Ann Allergy Asthma Immunol 123 (2019) 454–460

Contents lists available at ScienceDirect

Review

Autoimmunity in common variable immunodeficiency

Shradha Agarwal, MD; Charlotte Cunningham-Rundles, MD, PhD

Icahn School of Medicine at Mount Sinai, Division of Allergy and Clinical Immunology, Department of Medicine, New York, New York

Key Messages

- Besides infections, autoimmune or inflammatory diseases are common in patients with primary immunodeficiency. Common organ-specific autoimmunity in CVID patients include the gastrointestinal tract, lung, hematological system, joints, and skin.
- The onset of autoimmune disease in CVID varies, as does the severity and progression.
- Treatment of autoimmunity is often complicated by drug adverse effects and prolonged immunosuppression but includes high-dose immunoglobulin, corticosteroids, selected immunosuppressants, and other immune modulators.
- The mechanisms of these autoimmune/inflammatory diseases are still being investigated but likely involve defects in central and peripheral tolerance and autoreactive T and B cells.

ARTICLE INFO

Article history:
Received for publication May 31, 2019.
Received in revised form July 15, 2019.
Accepted for publication July 16, 2019.

ABSTRACT

Objective: Common variable immunodeficiency (CVID) is a primary immunodeficiency that is clinically heterogeneous, characterized by both infectious and noninfectious complications. Although the hallmark of disease presentation is commonly a history of recurrent sinopulmonary infections, autoimmunity and noninfectious inflammatory conditions are increasingly associated with CVID.

Data Sources: A comprehensive literature search using PubMed of basic science and clinical articles was performed.

Study Selections: Articles discussing the association of autoimmunity with primary immunodeficiency, specifically CVID, were selected.

Results: The most common autoimmune conditions are cytopenias, including immune thrombocytopenia purpura and hemolytic anemia, but organ-specific autoimmune/inflammatory complications involving the gastrointestinal, skin, joints, connective tissue, and respiratory tract. In most cases, immunoglobulin replacement therapy does not ameliorate or treat these inflammatory complications, and additional immunomodulatory treatments are needed.

Conclusion: Mechanisms producing these conditions are poorly understood but include cytokine and cellular inflammatory pathways, and loss of tolerance to self-antigens through the multiple signaling molecules and pathways common to tolerance and immune deficiency.

© 2019 American College of Allergy, Asthma & Immunology. Published by Elsevier Inc. All rights reserved.

Introduction

Common variable immunodeficiency (CVID) is the most common symptomatic primary immunodeficiency, with an estimated incidence of 1:50,000 to 1:25,000.[1,2] Key diagnostic elements include reduction in serum immunoglobulin G (IgG) and IgA or IgM levels by at least 2 standard deviations below age-appropriate reference levels, accompanied by impaired or absent antibody production. Reduced isotype switched memory B cells is characteristic of patients with CVID but not required for diagnosis by the International Consensus document for CVID disorders or European Society of Immune Deficiencies (ESID) criteria.[2–4] Other causes of hypogammaglobulinemia, including medications, protein loss, or malignancy, must be excluded. The CVID patients diagnosed in the third and fourth decade of life are likely to have experienced

Reprints: Shradha Agarwal, MD, One Gustave L. Levy Place, Box 1089, New York, New York 10029; E-mail: shradha.agarwal@mssm.edu.
Disclosures: None.
Funding Sources: None.

https://doi.org/10.1016/j.anai.2019.07.014
1081-1206/© 2019 American College of Allergy, Asthma & Immunology. Published by Elsevier Inc. All rights reserved.

diagnostic delay of 6 to 8 years after the first presenting manifestation. As discussed in the following sections, the pathogenesis of CVID remains complex; however, in the last decade, high-throughput gene sequencing has identified an increasing number of monogenic defects impairing B cell activation and leading to antibody deficiency in approximately 20% of CVID subjects.[2,5–7] However, given the diverse phenotypes of CVID, likely most patients have oligogenic or polygenic defects, and other epigenetic and environmental factors play a role in disease manifestations.

Clinically CVID presents as increased susceptibility to sinopulmonary infections; however, 30% to 50% of patients have additional noninfectious inflammatory conditions, including pulmonary and gastrointestinal inflammatory disease, lymphoid hyperplasia, granulomatous inflammation, splenomegaly, and various forms of autoimmunity, as noted in all large series (Table 1) (Fig 1).[8–11] Organ-specific autoimmunity commonly affects the hematologic and vascular system, gastrointestinal tract, lungs, joints, and endocrine organs. Treatment with antibiotics and IgG replacement has significantly decreased the mortality in CVID over the past few decades, primarily because of reduction in severe infections and sinopulmonary complications.[12] However, the noninfectious autoimmune/inflammatory complications are not resolved by IgG therapy and thus continue to contribute to morbidity and mortality.[8,10] Within the CVID research community, the focus has shifted toward identification of immune mechanisms contribute to these noninfectious manifestations and the discovery of more effective treatment strategies. The onset of autoimmune disease in CVID varies, as does the severity and progression. Here we will highlight clinical manifestations of the most common associated autoimmunity/inflammatory conditions, current treatment options, and considerations of pathogenesis.

Autoimmune Hematologic Disease

Autoimmunity in CVID most commonly manifests as autoimmune cytopenia, occurring in 4% to 20% of patients, usually with immune thrombocytopenic purpura (ITP), sometimes autoimmune hemolytic anemia (AIHA) usually occurring singly, but also occasionally consecutively, or concurrently as Evans' syndrome (Table 2) (Fig 2).[4,8] Autoimmunity also may be the first manifestation of the immune defect in an occasional patient who has never had a significant infection.[8,10,13] In 1 study, CVID subjects with ITP or Evans' syndrome tended to be younger than those who developed AIHA.[14] Autoimmune neutropenia also occurs in CVID, but it is rarer than ITP or AIHA and can be a single event or chronic.[15] In our US-based case series at Mount Sinai of 473 patients, ITP was reported at 14%, AIHA 7%, Evans' syndrome 4%, and autoimmune neutropenia less than 1%.[10] Within the USIDNET Registry, patients with autoimmune cytopenia were significantly more likely to have 1 or more other CVID-associated noninfectious complication, including lymphoproliferation, granulomatous disease, lymphomas, hepatic disease, interstitial lung diseases, or enteropathy.[16]

The diagnosis of autoimmune cytopenia relies on persistently abnormal complete blood counts with review of peripheral blood smear. If more than 1 cell lineage is affected, a bone marrow biopsy may be required to determine whether the cause is secondary to malignancy or bone marrow failure. Diagnosis of AIHA includes laboratory markers of hemolysis, including reticulocytosis, low serum haptoglobin levels, elevated lactate dehydrogenase level, and increased indirect bilirubin level. A positive Coombs test can help confirm a diagnosis of AIHA. Anti-platelet antibody tests are not standardized, and anti-neutrophil antibodies are not dependable in most cases; however, the lack of such antibodies does not exclude the diagnosis. Most autoimmune neutropenias are associated with normal marrow reserves, and the pathogenesis is attributable to antibody-mediated destruction or sequestration. Bone marrow biopsy typically reveals a hypercellular marrow and late maturational arrest. The CVID subjects with autoimmune cytopenias are likely to have significantly reduced numbers of isotype switched memory B cells in peripheral blood along with increased proportion of $CD21^{lo}$ B cells.[13,17,18] $CD21^{lo}$ B cells have been found in other autoimmune states and have unique characteristics, because they have been found to have an un-mutated B cell receptor, capable of IgM production and potentially polyreactive.

The treatment strategies used for cytopenias in CVID are essentially the same as applied for immune-competent patients. First-line therapy generally includes intravenous steroids (1 g methylprednisolone) followed by moderate doses of oral steroids tapered over several weeks or more or high-dose IVIg (1-2 g/kg) (Table 3). These also will often resolve ITP or AIHA in CVID. For subjects with recurrent cytopenias, chronic treatment with intravenous or subcutaneous immune globulin reduces the likelihood of additional episodes; however, a recent publication noted that a consistent IgG level of 700 mg/dL or more was required for this benefit to be observed.[19] Newer options for cytopenias include thrombopoietin-receptor agonists, which have also shown benefit.[20] In many cases, ITP or AIHA is accompanied by an enlarged spleen or cervical, mediastinal, or abdominal lymphadenopathy. However, splenectomy in patients with CVID should be avoided given the susceptibility to postoperative infections and sepsis with encapsulated organisms. For refractory cases, the avoidance of splenectomy has turned clinicians to immune modulating treatment options such as growth inhibitors (azathioprine, or mycophenolate mofetil). However, the risks of these drugs must be considered, and careful monitoring is essential. Much better options are provided by the B cell depletion monoclonal antibody (rituximab).[21,22] Although risk of post-rituximab hypogammaglobulinemia and persistent B-cell lymphopenia is present, CVID patients will require ongoing IgG supplementation nonetheless, and therefore this modality may be preferable to others (after steroid treatment).

The treatment of autoimmune neutropenia in CVID is not well established, partly because it is quite uncommon. High-dose IVIg or corticosteroids can be used if neutropenia is severe (absolute neutrophil count $< 500/mm^3$), but tapering may be difficult. Granulocyte-colony stimulating factor therapy can be used in cases of depletion of bone marrow reserves.[15] Similarly to ITP, rituximab also may offer benefit in management.

Autoimmune Pulmonary Disease

Infections are the most common pulmonary complication in CVID, but various forms of inflammatory lung disease occur in 30% to 60% of CVID patients.[8,10] This includes interstitial lung disease, which contributes to morbidity and mortality.[23,24] Although the actual incidence is unclear, it is commonly associated with evidence of systemic immune dysregulation, including previous cytopenias, lymphadenopathy, and splenomegaly.[23,25] Lung biopsies demonstrate benign lymphoproliferative pathology, including follicular bronchiolitis, lymphocytic interstitial pneumonitis, and nodular lymphoid hyperplasia.[23,26] Lymphocytic and granulomatous inflammation in the lung has been termed GLILD, and as for other lung pathologies in CVID, requires biopsy to diagnose.[27]

Radiologic findings depend on high-resolution computed tomography rather than x-ray, for more detailed identification of pulmonary nodules, bronchiectasis, or ground-glass opacities. Radiation exposure should be limited; therefore, very frequent or annual computed tomography examinations are not recommended. Pulmonary function tests with diffusion capacity for carbon monoxide can help estimate the degree of lung impairment. Given the overlap of features on high-resolution computed

Table 1
Overall Percentage of Inflammatory/Autoimmune Complications Reported in CVID Cohorts

Complication	ESID[a] (334 CVID)[8]	New York (473 CVID)[10]	Italy (224 CVID)[77]
Autoimmunity	NR	28.6	17.4
Autoimmune hemolytic anemia	0-8	7	2.7
Chronic lung disease	NR	28.5	34.2
Enteropathy	3-15	15.4	14
Granulomatous disease	2-16	9.7	6
Immune thrombocytopenia	0-13	14.2	5.6
Hepatomegaly	0-15	NR	NR
Hypothyroidism	0-7	NR	NR
Pernicious anemia	4-18	4	NR
Liver disease/ hepatitis	NR	9.1	NR
Lymphoid interstitial pneumonitis	0-10	NR	NR
Neutropenia	0-2	4	2.7
Psoriasis	0-6	1	NR
Thyrotoxicosis	0-2	NR	NR
Vitiligo	5-6	3	2.1

Percentages of inflammatory/autoimmune complications in patients with CVID across reported cohorts.
Abbreviation: NR, not reported.
[a]Across 5 European sites.

tomography with other lung diseases, biopsies from affected regions of the lung may be required to identify the type of cellular infiltrate.[28] Transbronchial biopsy may be inadequate because of patchy distribution of disease; therefore, open lung or video-assisted thorascopic biopsy should be considered to avoid sampling error.[27] Biopsy specimens should be stained for CD3+ T cells and CD19+/CD20+ B cells to characterizing the predominate cellular infiltrates and degree of damage. Additional stains for organisms and malignancy should be performed accordingly.

Treatment of lung disease is first based on ensuring adequate Ig replacement; increased doses producing higher trough levels (800-1000 mg/dL) have been suggested to reduce infectious lung disease.[29,30] Prophylactic antibiotics, such as azithromycin, are widely used in various doses, and in a recent study are clearly of benefit in reducing respiratory exacerbation and chronic infection-related pulmonary disease.[31] However, as for other inflammatory conditions in CVID, these measures will not treat or reverse noninfectious interstitial lung disease, and more aggressive management is usually required to prevent scarring and permanent lung damage.[32] Low doses of corticosteroids may be used acutely but have limited benefit long term. Lung biopsies demonstrate pulmonary infiltrates to include T cells, B cells, and macrophages. Therefore, therapy targeting both T and B cells concurrently, such as cyclophosphamide, cyclosporine, or azathioprine combined with rituximab, is required. Combination regimens have been shown to be effective for GLILD (Table 3).[28,33–35]

Autoimmune Gastrointestinal Disease

The gut-associated lymphoid tissue is the largest lymphoid organ in the body with a direct interface to the microbial universe; that gastrointestinal inflammatory conditions are common in CVID is not surprising. These occur in the stomach, small and large bowel, and also the liver. Treatment modalities, where known, are outlined (Table 3).

Stomach

Atrophic gastritis, resembling autoimmune gastritis, occurs in CVID and may lead to the development of pernicious anemia, without demonstrable anti-parietal cell antibodies. Treatment of pernicious anemia includes monthly replacement of vitamin B_{12}, careful monitoring of the gastric mucosa for *Helicobacter pylori*, and changes associated with malignancy.[36]

Small Bowel and Colon

For unclear reasons, chronic enteropathy may accompany autoimmunity, lymphoid hyperplasia, and splenomegaly in CVID.[8,9] The most frequently reported gastrointestinal symptom is transient or persistent diarrhea with weight loss, commonly because of the infectious organisms, *Giardia lamblia, Cryptosporidium parvum, Salmonella* species, cytomegalovirus, *Campylobacter jejuni,* or norovirus.[37,38] However, a chronic problem in CVID is a form of inflammatory bowel disease (IBD) resembling Crohn's or ulcerative

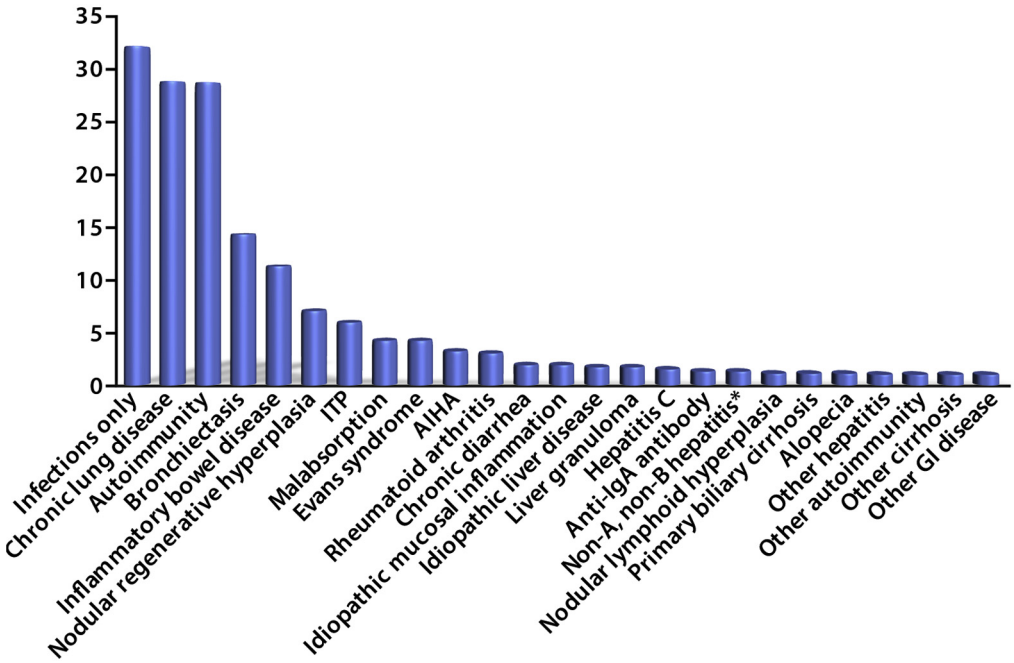

Figure 1. Inflammatory or autoimmune manifestations of New York CVID cohort. Resnick et al.[10] Percentage of patients (n = 473) with infections only, or others who had additional complications.

Table 2
CVID Associated Autoimmune Cytopenias in Two Registries

	USIDNET Registry[17] (N = 990)	ESID Registry[11] (N = 2700)
Any autoimmune cytopenia	101 (10.2%)	NR
Autoimmune cytopenia in ≥2 cell lines	38 (3.8%)	NR
Autoimmune cytopenia in 3 cell lines	4 (0.4%)	NR
Evan's syndrome	16 (1.6%)	NR
Immune thrombocytopenia	73 (7.4%)	162 (6.0%)
Hemolytic anemia	56 (5.1%)	110 (4.1%)
Autoimmune neutropenia	10 (1%)	NR

Numbers and type of autoimmune cytopenias reported across 2 large registries.
Abbreviation: NR, not reported.

colitis,[10,37,39] which leads to weight loss, chronic blood loss, abdominal pain, and malabsorption. The IBD-like disease typically manifests after the diagnosis of CVID has been made, but it also can be the presenting condition.

Diagnosis requires laboratory investigations to evaluate protein loss, inflammatory markers, nutritional status, stool studies, radiologic imaging, and endoscopy with biopsy of the intestinal mucosa. Fecal calprotectin is a useful marker for bowel inflammation and can be elevated in the setting of bowel infection or inflammatory enteropathy. Alpha-1 antitrypsin in stool may reveal excess protein loss. Clinical history of CVID must be provided to the pathologists, because many of the features on histology may resemble other inflammatory diseases; however, the paucity or absence of plasma cells distinguish CVID patients. The small bowel villous flattening in CVID appears to be an immune-mediated/inflammatory phenomenon grossly resembling celiac sprue. The villous atrophy can cause malabsorption, weight loss, diarrhea, hypoalbuminemia, anemia, and low blood $CD4^+$ lymphocyte levels. Despite its gross resemblance to celiac disease, several features help distinguish this, such as the lack of plasma cells and absence of detectable serum antibodies against gliadin, reticulin, tissue transglutaminase, and endomysium. Endoscopic features include longitudinal ulcers and cobblestone appearance, whereas histopathology includes intraepithelial lymphocytosis, lymphoid aggregates, granulomas, and crypt distortion. These patterns in CVID biopsy specimens often mimic lymphocytic colitis, collagenous colitis, and colitis associated with graft-vs-host disease. Nodular lymphoid hyperplasia in the gut can be seen as nodules on radiologic or endoscopic evaluation distributed diffusely throughout the stomach, ileum, and colon.

Common variable immunodeficiency–associated colitis is often difficult to control and unresponsive to standard IBD therapies. Immunoglobulin replacement does not ameliorate the IBD-like disease as with other autoimmune or inflammatory conditions. Thus, treatment focuses on adequate nutritional support with replacement of water-soluble vitamins and antiresorptives for prevention of osteoporosis. Severe cases of malabsorption may require an elemental diet or total parenteral nutrition. Low-dose corticosteroids can be used, although higher doses can lead to a significant risk of infections. Other options include antibiotics to eliminate bacterial overgrowth, oral budesonide, and immunosuppressants, including 5-aminosalicylate agents, 6-MP, and AZA.[40,41] These medications do not significantly compromise immune function, and continued IgG replacement reduces the possibility of infectious complications to some degree. Although resemblance to gluten enteropathy has been noted in CVID enteropathy, gluten withdrawal is generally ineffective. As with autoimmune cytopenias, targeted biological therapies in gastrointestinal inflammation, such as anti-tumor necrosis factor-alpha (TNF-α), interleukin 12, and interleukin 23 antagonist, have been used with some benefit in severe cases, as based on case reports. However, patients with significant T-cell defects require monitoring for opportunistic infections.[42] Use of anti-$\alpha 4\beta 7$ integrin, vedolizumab, could potentially worsen enteropathy by blocking extravasation of Tregs into the gut mucosa[42]; however, this therapy has been used with some success in CVID.[43]

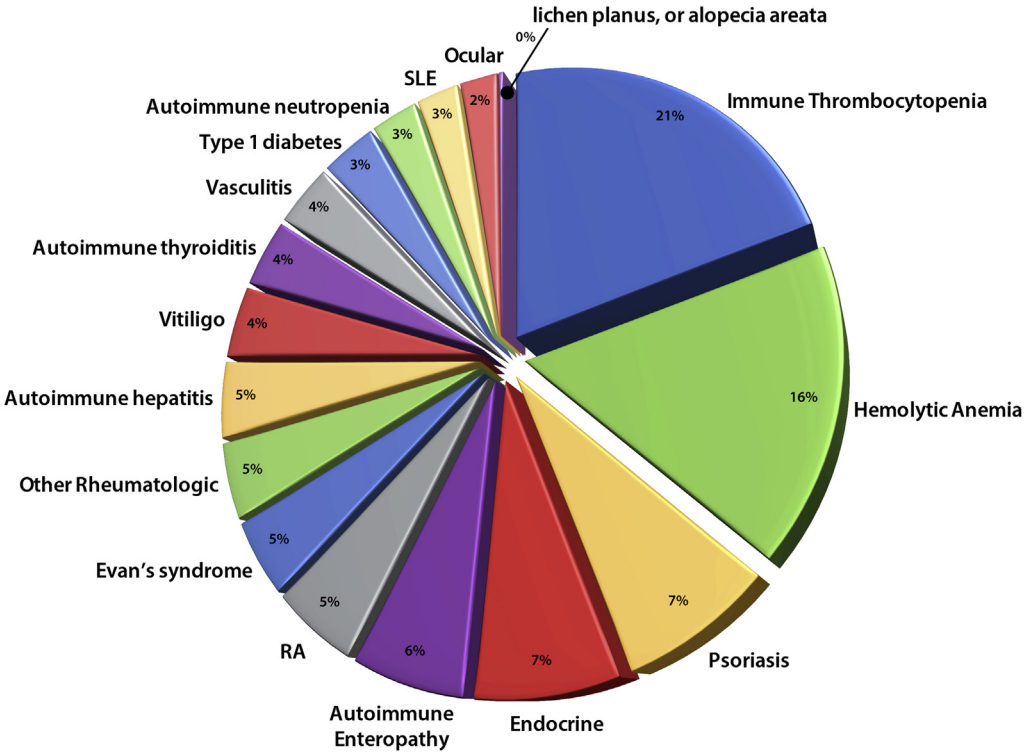

Figure 2. Autoimmunity in CVID cohort of USIDNET. Feuille et al.[16] Autoimmune conditions (n = 351) in 990 CVID patients in USIDNET.

Table 3
Treatment of CVID Associated Autoimmunity

	Autoimmunity	Treatments
Hematologic	ITP, AIHA, AIN	Corticosteroids, high-dose immunoglobulin, rituximab; thrombopoietin receptor agonists, sirolimus, splenectomy
Gastrointestinal	IBD, small bowel villous flattening, NLH, cirrhosis, hepatitis, pernicious anemia, atrophic gastritis	Corticosteroids, antibiotics, 6-MP, AZA, cyclosporine, adalimumab, entanercept, infliximab, rituximab, vedolizumab
Pulmonary	Lymphoid interstitial lung disease, GLILD	Corticosteroids, cyclophosphamide, cyclosporine, azathioprine, infliximab, rituximab, mycophenylate mofetil (MMF)
Dermatological	Alopecia totalis, eczema, vitiligo, psoriasis, lichen planus, granulomatous	Emolliants, topical steroids, rituximab
Rheumatological	SLE, RA, JRA, SS, vasculitis	DMARDS, methotrexate, mycophenolate mofetil (MMF), cyclophosphamide, rituximab, infliximab, abatacept

Abbreviations: AIHA, autoimmune hemolytic amenia; AIN, autoimmune neutropenia; AZA, azathioprine; DMARDS, disease-modifying antirheumatic drugs; GLILD, granulomatous and lymphocytic interstitial lung disease; IBD, inflammatory bowel disease; ITP, immune thrombocytopenic purpura; JRA, juvenile rheumatoid arthritis; 6-MP, mercaptopurine; NLH, nodular lymphoid hyperplasia; RA, rheumatoid arthritis; SLE, systemic lupus erythematosus; SS, Sjögren's syndrome.

Liver Disease

The noninfectious CVID-associated liver diseases include autoimmune and inflammatory conditions, primary biliary cirrhosis, primary sclerosing cholangitis, and nodular regenerative hyperplasia.[44] These can lead to chronic cholestasis and difficult-to-manage portal hypertension.[10,45] Patients may be asymptomatic or present with fatigue, nausea, vomiting, jaundice, ascites, or hepatosplenomegaly and found to have esophageal varices. Laboratory evaluations demonstrate persistent elevations of alkaline phosphatase and liver enzymes with or without significant increases in bilirubin. Imaging by ultrasound and computed tomography/magnetic resonance imaging to evaluate structural changes and liver biopsy are required for diagnosis.[46] Histopathology demonstrates regenerative liver nodules, nonspecific portal and lobular inflammation, interface hepatitis, lymphocyte infiltration without plasma cells, granulomas, fibrosis, macrovesicular steatosis, and neogenesis of biliary ducts.[45] Treatment for autoimmune liver disease in CVID includes corticosteroids or immunomodulators[34,35] and ursodeoxycholic acid if biliary damage is present.[47] Liver transplantation has been performed,[48] but with limited survival after transplantation (55% at 3 and 5 years).[49]

Table 4
Summary of the Main Genetic Defects in CVID

Type of defect	Inheritance	Laboratory
B cell development		
IKZF1	AD	Low IgG and IgA or IgM
B cell receptor activation		
CD 19 deficiency	AR	Low IgG and IgA or IgM
CD 81 deficiency	AR	Low IgG, low or normal IgA and IgM
CD 20 deficiency	AR	Low IgG, normal or elevated IgM and IgA
CD 21 deficiency	AR	Low IgG, impaired anti-pneumococcal response
CD 27	AR	Hypogammaglobulinemia
B cell activation/maturation		
TACI deficiency	AD; AR	Low IgG and IgA or IgM
BAFF receptor deficiency	AR	Low IgG and IgM
TWEAK deficiency	AD	Low IgM and A, lack of anti-pneumococcal antibody
ICOS	AR	Low IgG and IgA or IgM
Control of lymphocyte responses		
LRBA	AR	Hypogammaglobulinemia, low IgG and IgA
CTLA-4	AD	Hypogammaglobulinemia, low IgG and IgA; sometimes IgM
NFKB1 deficiency	AD	Normal or low IgG, IgA, IgM, low or normal B cells, low B cells
NFKB2 deficiency	AD	Low serum IgG, A and M; low B cell numbers
PIK3CD mutation	AD	All isotypes decreased
PIK3R1	AD; AR	Hypogammaglobulinemia, increased IgM
Required cytokines		
IL-21	AR	Impaired B-cell differentiation
IL21R	AR	Low IgG, defective class-switched B cells and defective antibody responses

AD, autosomal dominant; AR, autosomal recessive; BAFF, B-cell activating factor; CD, cluster of differentiation; CTLA, cytotoxic T-lymphocyte–associated antigen 4; ICOS, inducible T-cell co-stimulator; Ig, immunoglobulin; IKZF1, *IKAROS* Family Zinc Finger 1; IL, interleukin; LRBA, lipopolysaccharide-responsive beige-like anchor protein; NFKB, nuclear factor kappaB; PIK, phosphoinositide-3-kinase; TACI, transmembrane activator and CAML interactor; TWEAK, TNF-like weak inducer of apoptosis.

Autoimmune Rheumatologic Disease

The association between CVID and rheumatologic diseases has been reported in many studies.[8,10,50] These disorders most commonly include adult and juvenile forms of chronic inflammatory arthritis, leading to symmetric involvement of few or many joints, commonly the knees, ankles, and hands, and may result in joint destruction. Less frequently reported are systemic lupus erythematosus, Raynaud's syndrome vasculitis, mixed connective tissue disorder, inflammatory myositis, Behcet's disease, and Sjogren's syndrome.[51,52] Among a retrospective analysis of 870 adult and pediatric patients within the USIDNET registry, a third of patients with rheumatologic conditions had additional inflammatory complications or malignancy.[50] Some cohorts reported CVID patients with rheumatological diseases as having slightly higher baseline IgG levels, autoantibody formation, and a family history of autoimmunity. However, given the rarity of these manifestations, the exact mechanism is still unknown,[4,10,53] although auto-reactive B cells are likely to be involved.[54,55]

Mycoplasma species, such as *M. pneumoniae*, *M. salivarium*, and *M. hominis*, and Ureaplasma urealyticum are the most common causes of septic arthritis.[56] Because of antibody deficiency, results of serologic testing may be negative in these patients or inconclusive if patients are already on IgG replacement. Therefore, other clinical evaluation including physical examination and imaging (x-ray, magnetic resonance imaging) are most helpful in making the diagnosis. Histopathology of synovial biopsy may demonstrate synovial hyperplasia and capillary proliferation without major lymphocytic or polymorphonuclear infiltrate, but few to absent B cells, no plasma cells, and T cell infiltrate may be composed of CD8+ cells. Consultation with a rheumatologist is advised to reduce delay in diagnosis and establish therapy. Rheumatologic disease is treated in the same fashion as for patients without CVID; with trials of immunosuppressive drugs such as methotrexate, mycophenolate, or cyclophosphamide, or newer biologic therapies targeting tumor necrosis factor, B-cells, and cytokines, while continuing IgG replacement.

Autoimmune Dermatologic Disease

Skin manifestations are common in more rare primary immunodeficiency disorders, such as hyper-IgE syndrome, severe

combined immunodeficiency (SCID), and granulocyte defects, but have been less reported in CVID. Case reports of dermatological involvement in CVID include alopecia totalis, lichen planus, psoriasis, and vitiligo.[8,47,57] Granulomas as mentioned previously are more frequently found in lungs and lymphoid tissue, but also can be found in the skin,[58] where these may be the presenting clinical manifestation of CVID. Routine dermatological evaluation will allow for timely diagnosis, including biopsy and treatment. The general approach to treatment includes immunodulatory therapies topically or systemically as would be prescribed for immunocompetent patients.

Pathogenesis of Autoimmunity in CVID

Why is autoimmunity so common in CVID? As for other congenital immune defects, the answer to this question is complex and not truly elucidated.[59] However, the reasons that have been linked include failure to counterselect polyspecific/self-reactive clones that normally arise in the bone marrow in even healthy humans,[60,61] the immature B cell development that is the hallmark of CVID,[4,18] and high levels of factors in serum, which lead to increased B cell proliferation, including B cell activating factor (BAFF) and a proliferation-inducing ligand. These factors are known to particularly drive immature B cells.[62] For some time we have known of loss of regulatory T cells (Treg)[63] in CVID, especially in those with autoimmunity. An additional cause is likely to be chronic antigen stimulation, which could arise from mucosal barrier dysfunction.

In any discussion of causation of autoimmunity in CVID, one must consider the role of genes in this syndrome, particularly genetic mutations that would also foster autoimmunity. Although the first genes identified in CVID were autosomal recessive genes, an increasing number of autosomal dominant genes with variable penetrance have been documented, accounting for up to 30% of patients in some reports (Table 4).[5–7] The genes identified reflect the complex requirements of B cell development, antigen signaling, activation, survival, and maturation to the plasma cell stage. Autosomal recessive genes include the gene encoding the T-cell surface receptor, inducible T-cell costimulator (*ICOS*),[64] the B-cell activating factor receptor (BAFF-R),[65] and the genes for the B cell receptor complex–associated proteins, CD19, CD20, CD21, CD81, and CD27.[66] Mutations in the calcium-modulating cyclophilin ligand interactor (TACI) are found in 8% to 10% of CVID patients, usually in the heterozygous state, suggesting either dominant-negative effect or haploinsufficiency.[67,68] Clinically and in the context of this review, these patients have a particular propensity to autoimmune manifestations and lymphoid hyperplasia, potentially because of lack of normal mechanisms of establishing tolerance.[60,69] In addition, mutations in a number of genes involved in immune regulation may also lead to a clinical picture of CVID: these include autosomal recessive mutations in lipopolysaccharide-responsive beige-like anchor protein (LRBA),[70] in which patients have recurrent infections, but usually also autoimmunity, with almost autoimmune/lymphoproliferative-like features.[71] Similar to defects of LRBA are heterozygous autosomal dominant mutations in CTLA4, which is often complicated by autoimmunity such as lymphoid hyperplasia, enteropathy, and granulomatous infiltrative lung disease.[72] Other autosomal dominant mutations that may produce CVID (or more of a hyper IgM) phenotype are in autosomal dominant mutations in the catalytic subunit (PIK3CD) of PI3K.[73,74] Mutations in transcription factors of the nuclear factor kappaB (NFκB) family have been described in increasing numbers of subjects with "CVID," particularly autosomal dominant defects in the *NFKB1* subunit leading to antibody deficiency, infections, autoimmunity, and lymphoproliferative disease,[75] and heterozygous autosomal dominant mutations in *NFKB*2 leading to early onset hypogammaglobulinemia with recurrent infections and autoimmunity in some, but in others also autoimmune endocrine abnormities.[76] Genetic studies in CVID have been approached by both targeted panels and also by whole exome sequencing, but the clinical question that arises is who should be tested. Although testing is not required for the diagnosis of CVID, for subjects with accompanying clinically prominent autoimmune or inflammatory features, genetic insights may lead to genetic counselling or more targeted therapeutic options.

Conclusion

Although it may seem paradoxical, autoimmune manifestations occur not infrequently in patients with primary immunodeficiency. With improvements in antimicrobials and IgG therapy, patients' survival has increased, allowing for recognition of other disease complications, namely a variety of autoimmunity and inflammatory diseases, in these patients. These autoimmune diseases may have the typical signs and symptoms as in immunocompetent patients; however, treatment is often complicated by the underlying immunodeficiency. Mechanisms of autoimmunity in CVID continue to be investigated and likely involve defects in the effector or regulatory immune responses of self-tolerance.

References

1. Bonilla FA, Barlan I, Chapel H, et al. International Consensus Document (ICON): Common variable immunodeficiency disorders. *J Allergy Clin Immunol Pract*. 2016;4:38–59.
2. Picard C, Bobby Gaspar H, Al-Herz W, et al. International Union of Immunological Societies: 2017 Primary Immunodeficiency Diseases Committee Report on Inborn Errors of Immunity. *J Clin Immunol*. 2018;38:96–128.
3. Seidel MG, Kindle G, Gathmann B, et al. The European Society for Immunodeficiencies (ESID) Registry Working Definitions for the Clinical Diagnosis of Inborn Errors of Immunity. *J Allergy Clin Immunol Pract*. 2019;7(6):1763–1770.
4. Wehr C, Kivioja T, Schmitt C, et al. The EUROclass trial: defining subgroups in common variable immunodeficiency. *Blood*. 2008;111:77–85.
5. Bogaert DJ, Dullaers M, Lambrecht BN, Vermaelen KY, De Baere E, Haerynck F. Genes associated with common variable immunodeficiency: one diagnosis to rule them all? *J Med Genet*. 2016;53:575–590.
6. Maffucci P, Filion CA, Boisson B, et al. Genetic diagnosis using whole exome sequencing in common variable immunodeficiency. *Front Immunol*. 2016;7:220.
7. de Valles-Ibanez G, Esteve-Sole A, Piquer M, et al. Evaluating the genetics of common variable immunodeficiency: monogenetic model and beyond. *Front Immunol*. 2018;9:636.
8. Chapel H, Lucas M, Lee M, et al. Common variable immunodeficiency disorders: division into distinct clinical phenotypes. *Blood*. 2008;112:277–286.
9. Gathmann B, Mahlaoui N, Ceredih, et al. Clinical picture and treatment of 2212 patients with common variable immunodeficiency. *J Allergy Clin Immunol*. 2014;134:116–126.
10. Resnick ES, Moshier EL, Godbold JH, Cunningham-Rundles C. Morbidity and mortality in common variable immune deficiency over 4 decades. *Blood*. 2012;119:1650–1657.
11. Odnoletkova I, Kindle G, Quinti I, et al. The burden of common variable immunodeficiency disorders: a retrospective analysis of the European Society for Immunodeficiency (ESID) registry data. *Orphanet J Rare Dis*. 2018;13:201.
12. Perez EE, Orange JS, Bonilla F, et al. Update on the use of immunoglobulin in human disease: a review of evidence. *J Allergy Clin Immunol*. 2017;139:S1–S46.
13. Warnatz K, Voll RE. Pathogenesis of autoimmunity in common variable immunodeficiency. *Front Immunol*. 2012;3:210.
14. Wang J, Cunningham-Rundles C. Treatment and outcome of autoimmune hematologic disease in common variable immunodeficiency (CVID). *J Autoimmun*. 2005;25:57–62.
15. Guffroy A, Mourot-Cottet R, Gerard L, et al. Neutropenia in patients with common variable immunodeficiency: a rare event associated with severe outcome. *J Clin Immunol*. 2017;37:715–726.
16. Feuille EJ, Anooshiravani N, Sullivan KE, Fuleihan RL, Cunningham-Rundles C. Autoimmune cytopenias and associated conditions in CVID: a report from the USIDNET Registry. *J Clin Immunol*. 2018;38:28–34.
17. Boileau J, Mouillot G, Gerard L, et al. Autoimmunity in common variable immunodeficiency: correlation with lymphocyte phenotype in the French DEFI study. *J Autoimmun*. 2011;36:25–32.
18. Sanchez-Ramon S, Radigan L, Yu JE, Bard S, Cunningham-Rundles C. Memory B cells in common variable immunodeficiency: clinical associations and sex differences. *Clin Immunol*. 2008;128:314–321.
19. Scheuerlein P, Pietsch L, Camacho-Ordonez N, et al. Is it safe to switch from intravenous immunoglobulin to subcutaneous immunoglobulin in patients

with common variable immunodeficiency and autoimmune thrombocytopenia? *Front Immunol*. 2018;9:1656.
20. Carrabba M, Barcellini W, Fabio G. Use of thrombopoietin-receptor agonist in CVID-associated immune thrombocytopenia. *J Clin Immunol*. 2016;36:434–436.
21. Gobert D, Bussel JB, Cunningham-Rundles C, et al. Efficacy and safety of rituximab in common variable immunodeficiency-associated immune cytopenias: a retrospective multicentre study on 33 patients. *Br J Haematol*. 2011;155:498–508.
22. Ghanima W, Godeau B, Cines DB, Bussel JB. How I treat immune thrombocytopenia: the choice between splenectomy or a medical therapy as a second-line treatment. *Blood*. 2012;120:960–969.
23. Bates CA, Ellison MC, Lynch DA, Cool CD, Brown KK, Routes JM. Granulomatous-lymphocytic lung disease shortens survival in common variable immunodeficiency. *J Allergy Clin Immunol*. 2004;114:415–421.
24. Maglione PJ, Overbey JR, Cunningham-Rundles C. Progression of common variable immunodeficiency interstitial lung disease accompanies distinct pulmonary and laboratory findings. *J Allergy Clin Immunol Pract*. 2015;3:941–950.
25. Hartono S, Motosue MS, Khan S, et al. Predictors of granulomatous lymphocytic interstitial lung disease in common variable immunodeficiency. *Ann Allergy Asthma Immunol*. 2017;118:614–620.
26. Maglione PJ, Ko HM, Beasley MB, Strauchen JA, Cunningham-Rundles C. Tertiary lymphoid neogenesis is a component of pulmonary lymphoid hyperplasia in patients with common variable immunodeficiency. *J Allergy Clin Immunol*. 2014;133:535–542.
27. Rao N, Mackinnon AC, Routes JM. Granulomatous and lymphocytic interstitial lung disease: a spectrum of pulmonary histopathologic lesions in common variable immunodeficiency—histologic and immunohistochemical analyses of 16 cases. *Hum Pathol*. 2015;46:1306–1314.
28. Chase NM, Verbsky JW, Hintermeyer MK, et al. Use of combination chemotherapy for treatment of granulomatous and lymphocytic interstitial lung disease (GLILD) in patients with common variable immunodeficiency (CVID). *J Clin Immunol*. 2013;33:30–39.
29. Ballow M. Optimizing immunoglobulin treatment for patients with primary immunodeficiency disease to prevent pneumonia and infection incidence: review of the current data. *Ann Allergy Asthma Immunol*. 2013;111:S2–S5.
30. Orange JS, Grossman WJ, Navickis RJ, Wilkes MM. Impact of trough IgG on pneumonia incidence in primary immunodeficiency: a meta-analysis of clinical studies. *Clin Immunol*. 2010;137:21–30.
31. Milito C, Pulvirenti F, Cinetto F, et al. Double-blind, placebo-controlled, randomized trial on low-dose azithromycin prophylaxis in patients with primary antibody deficiencies. *J Allergy Clin Immunol*. 2019. https://doi.org/10.1016/j.jaci.2019.01.051.
32. Lucas M, Lee M, Lortan J, Lopez-Granados E, Misbah S, Chapel H. Infection outcomes in patients with common variable immunodeficiency disorders: relationship to immunoglobulin therapy over 22 years. *J Allergy Clin Immunol*. 2010;125:1354–1360.
33. Malbran A, Juri MC, Fernandez Romero DS. Common variable immunodeficiency and granulomatosis treated with infliximab. *Clin Immunol*. 2010;134:359–360.
34. Boursiquot JN, Gerard L, Malphettes M, et al. Granulomatous disease in CVID: retrospective analysis of clinical characteristics and treatment efficacy in a cohort of 59 patients. *J Clin Immunol*. 2013;33:84–95.
35. Franxman TJ, Howe LE, Baker Jr JR. Infliximab for treatment of granulomatous disease in patients with common variable immunodeficiency. *J Clin Immunol*. 2014;34:820–827.
36. Agarwal S, Mayer L. Diagnosis and treatment of gastrointestinal disorders in patients with primary immunodeficiency. *Clin Gastroenterol Hepatol*. 2013;11:1050–1063.
37. Daniels JA, Lederman HM, Maitra A, Montgomery EA. Gastrointestinal tract pathology in patients with common variable immunodeficiency (CVID): a clinicopathologic study and review. *Am J Surg Pathol*. 2007;31:1800–1812.
38. Oksenhendler E, Gerard L, Fieschi C, et al. Infections in 252 patients with common variable immunodeficiency. *Clin Infect Dis*. 2008;46:1547–1554.
39. Agarwal S, Smereka P, Harpaz N, Cunningham-Rundles C, Mayer L. Characterization of immunologic defects in patients with common variable immunodeficiency (CVID) with intestinal disease. *Inflamm Bowel Dis*. 2011;17:251–259.
40. Elnachef N, McMorris M, Chey WD. Successful treatment of common variable immunodeficiency disorder-associated diarrhea with budesonide: a case report. *Am J Gastroenterol*. 2007;102:1322–1325.
41. Agarwal S, Mayer L. Pathogenesis and treatment of gastrointestinal disease in antibody deficiency syndromes. *J Allergy Clin Immunol*. 2009;124:658–664.
42. Uzzan M, Ko HM, Mehandru S, Cunningham-Rundles C. Gastrointestinal disorders associated with common variable immune deficiency (CVID) and chronic granulomatous disease (CGD). *Curr Gastroenterol Rep*. 2016;18:17.
43. Boland BS, Riedl MA, Valasek MA, Crowe SE, Sandborn WJ. Vedolizumab in patients with common variable immune deficiency and gut inflammation. *Am J Gastroenterol*. 2017;112:1621.
44. Fuss IJ, Friend J, Yang Z, et al. Nodular regenerative hyperplasia in common variable immunodeficiency. *J Clin Immunol*. 2013;33:748–758.
45. Daniels JA, Torbenson M, Vivekanandan P, Anders RA, Boitnott JK. Hepatitis in common variable immunodeficiency. *Hum Pathol*. 2008;40(4):484–488.
46. Song J, Lleo A, Yang GX, et al. Common variable immunodeficiency and liver involvement. *Clin Rev Allergy Immunol*. 2018;55:340–351.
47. Xiao X, Miao Q, Chang C, Gershwin ME, Ma X. Common variable immunodeficiency and autoimmunity: an inconvenient truth. *Autoimmun Rev*. 2014;13:858–864.
48. Montalti R, Mocchegiani F, Vincenzi P, Svegliati Baroni G, Nicolini D, Vivarelli M. Liver transplantation in patients with common variable immunodeficiency: a report of two cases. *Ann Transplant*. 2014;19:541–544.
49. Azzu V, Elias JE, Duckworth A, et al. Liver transplantation in adults with liver disease due to common variable immunodeficiency leads to early recurrent disease and poor outcome. *Liver Transpl*. 2018;24:171–181.
50. Gutierrez MJ, Sullivan KE, Fuleihan R, Consortium U, Bingham 3rd CO. Phenotypic characterization of patients with rheumatologic manifestations of common variable immunodeficiency. *Semin Arthritis Rheum*. 2018;48:318–326.
51. Abolhassani H, Amirkashani D, Parvaneh N, et al. Autoimmune phenotype in patients with common variable immunodeficiency. *J Invest Allergol Clin Immunol*. 2013;23:323–329.
52. Ramirez-Vargas N, Arablin-Oropeza SE, Mojica-Martinez D, et al. Clinical and immunological features of common variable immunodeficiency in Mexican patients. *Allergol Immunopathol (Madr)*. 2014;42:235–240.
53. Maglione PJ. Autoimmune and lymphoproliferative complications of common variable immunodeficiency. *Curr Allergy Asthma Rep*. 2016;16:19.
54. Kuehn HS, Boisson B, Cunningham-Rundles C, et al. Loss of B cells in patients with heterozygous mutations in IKAROS. *N Engl J Med*. 2016;374:1032–1043.
55. Rao DA, Gurish MF, Marshall JL, et al. Pathologically expanded peripheral T helper cell subset drives B cells in rheumatoid arthritis. *Nature*. 2017;542:110–114.
56. Fernandez-Castro M, Mellor-Pita S, Citores MJ, et al. Common variable immunodeficiency in systemic lupus erythematosus. *Semin Arthritis Rheum*. 2007;36:238–245.
57. Megna M, Pecoraro A, Balato N, et al. Psoriasis in a cohort of patients with common variable immunodeficiency. *Br J Dermatol*. 2019;180:935–936.
58. Plana Pla A, Bassas-Vila J, Roure S, Ferrandiz C. Necrotizing and sarcoidal granulomas in the skin and synovial membrane, associated with common variable immunodeficiency. *Clin Exp Dermatol*. 2015;40:379–382.
59. van de Ven AA, Warnatz K. The autoimmune conundrum in common variable immunodeficiency disorders. *Curr Opin Allergy Clin Immunol*. 2015;15:514–524.
60. Romberg N, Chamberlain N, Saadoun D, et al. CVID-associated TACI mutations affect autoreactive B cell selection and activation. *J Clin Invest*. 2013;123:4283–4293.
61. Romberg N, Le Coz C, Glauzy S, et al. Patients with common variable immunodeficiency with autoimmune cytopenias exhibit hyperplastic yet inefficient germinal center responses. *J Allergy Clin Immunol*. 2019;143:258–265.
62. Maglione PJ, Gyimesi G, Cols M, et al. BAFF-driven B cell hyperplasia underlies lung disease in common variable immunodeficiency. *JCI Insight*. 2019. https://doi.org/10.1172/jci.insight.122728.
63. Fevang B, Yndestad A, Sandberg WJ, et al. Low numbers of regulatory T cells in common variable immunodeficiency: association with chronic inflammation in vivo. *Clin Exp Immunol*. 2007;147:521–525.
64. Grimbacher B, Hutloff A, Schlesier M, et al. Homozygous loss of ICOS is associated with adult-onset common variable immunodeficiency. *Nat Immunol*. 2003;4:261–268.
65. Warnatz K, Salzer U, Rizzi M, et al. B-cell activating factor receptor deficiency is associated with an adult-onset antibody deficiency syndrome in humans. *Proc Natl Acad Sci U S A*. 2009;106:13945–13950.
66. van Montfrans JM, Hoepelman AI, Otto S, et al. CD27 deficiency is associated with combined immunodeficiency and persistent symptomatic EBV viremia. *J Allergy Clin Immunol*. 2012;129:787–793.
67. Castigli E, Wilson SA, Garibyan L, et al. TACI is mutant in common variable immunodeficiency and IgA deficiency. *Nat Genet*. 2005;37:829–834.
68. Salzer U, Chapel HM, Webster AD, et al. Mutations in TNFRSF13B encoding TACI are associated with common variable immunodeficiency in humans. *Nat Genet*. 2005;37:820–828.
69. Salzer U, Bacchelli C, Buckridge S, et al. Relevance of biallelic versus monoallelic TNFRSF13B mutations in distinguishing disease-causing from risk-increasing TNFRSF13B variants in antibody deficiency syndromes. *Blood*. 2009;113:1967–1976.
70. Lopez-Herrera G, Tampella G, Pan-Hammarstrom Q, et al. Deleterious mutations in LRBA are associated with a syndrome of immune deficiency and autoimmunity. *Am J Hum Genet*. 2012;90:986–1001.
71. Serwas NK, Kansu A, Santos-Valente E, et al. Atypical manifestation of LRBA deficiency with predominant IBD-like phenotype. *Inflamm Bowel Dis*. 2015;21:40–47.
72. Schwab C, Gabrysch A, Olbrich P, et al. Phenotype, penetrance, and treatment of 133 cytotoxic T-lymphocyte antigen 4-insufficient subjects. *J Allergy Clin Immunol*. 2018;142(6):1932–1946.
73. Angulo I, Vadas O, Garcon F, et al. Phosphoinositide 3-kinase delta gene mutation predisposes to respiratory infection and airway damage. *Science*. 2013;342:866–871.
74. Lucas CL, Kuehn HS, Zhao F, et al. Dominant-activating germline mutations in the gene encoding the PI(3)K catalytic subunit p110delta result in T cell senescence and human immunodeficiency. *Nat Immunol*. 2014;15:88–97.
75. Tuijnenburg P, Lango Allen H, Burns SO, et al. Loss-of-function nuclear factor kappaB subunit 1 (NFKB1) variants are the most common monogenic cause of common variable immunodeficiency in Europeans. *J Allergy Clin Immunol*. 2018;142(4):1285–1296.
76. Chen K, Coonrod EM, Kumanovics A, et al. Germline mutations in NFKB2 implicate the noncanonical NF-kappaB pathway in the pathogenesis of common variable immunodeficiency. *Am J Hum Genet*. 2013;93:812–824.
77. Quinti I, Soresina A, Spadaro G, et al. Long-term follow-up and outcome of a large cohort of patients with common variable immunodeficiency. *J Clin Immunol*. 2007;27:308–316.